Effect of Ultrasound Therapy on the Repair of Gastrocnemius Muscle Injury in Rats

Maria Cristina Piedade[1], Milena Sanches Galhardo[2], Cláudia Naves Battlehner[1], Marcelo Alves Ferreira[1], Olga Maria Toledo[2], Elia Garcia Caldini[1]

[1]Laboratory of Cell Biology, The University of São Paulo School of Medicine, [2]Department of Morphology, The Federal University of São Paulo, São Paulo, Brazil

BACKGROUND

Even though the muscle retains its ability to regenerate following injury, muscle healing has been found to be very slow, sometimes, depending on the severity of the muscle injury, with an incomplete muscle recovery. One challenging problem in traumatology and in sports medicine is to find clinically feasible treatment modalities that enhance the cell proliferation phase and prevent the occurrence of fibrosis during the reparative process. In spite of over 60 years of a wide range of clinical use, authors affirmed that it is difficult to provide sufficient evidence to establish the clinical efficacy of ultrasound (US) therapy. Considering that US treatment stimulates both proliferation of myogenic cells and collagen deposition which, theorically, could impair further cell proliferation, it was thought to be of interest to proceed to a quantitative study of collagen and myogenic cells in a rat muscle lacerated injury model treated by pulsed US.

MATERIALS AND METHOD

Thirty adult male Wistar rats (approximately 90 days old and weighting 350–400 g) were randomly assigned into six groups. The gastrocnemius muscle hemitransection was made at 2.5 cm from the calcaneus flexed at 90. The laceration was approximately 1.0 cm wide 0.3 mm deep, located laterally to the vessel-nervous bundle (popliteal artery and tibialis nerve). We compared untreated operated controls with animals treated daily with 1MHz pulsed US(50%) at 0.57 W/cm² for 5min (beginning 2 days post-trauma). Five treated and five control animals were sacrificed at 4, 7 or 14 days post-trauma. Morphometric techniques in association with the Picrosirius-polarization (PSP) method (for collagen identification) and with immunodetection of desmin (a myogenic cells marker) were carried out in tissue sections.

RESULTS

HISTOLOGY AND IMMUNOHISTOCHEMICAL STUDY

QUALITATIVE ASPECTS OF THE TISSUE STRUCTURE

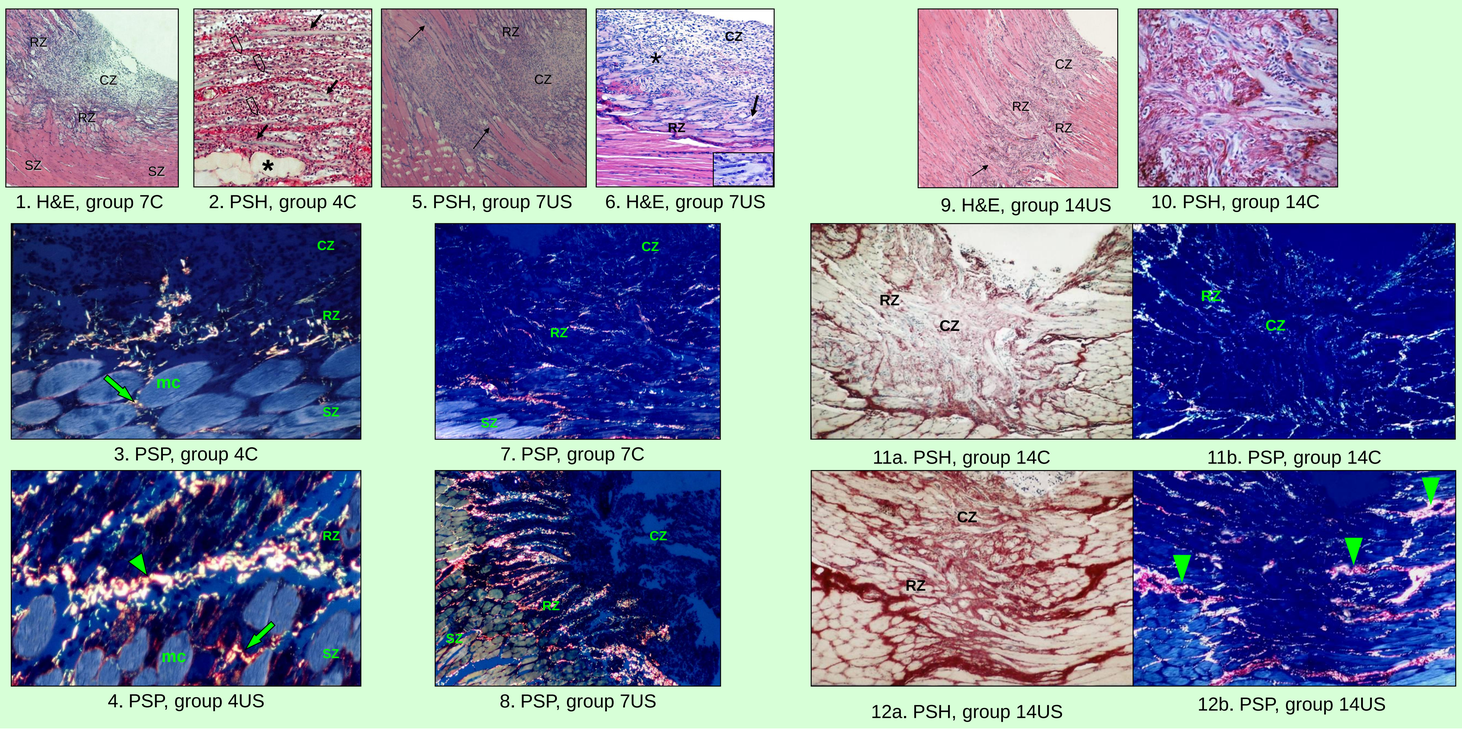

1. H&E, group 7C
2. PSH, group 4C
3. PSP, group 4C
4. PSP, group 4US
5. PSH, group 7US
6. H&E, group 7US
7. PSP, group 7C
8. PSP, group 7US
9. H&E, group 14US
10. PSH, group 14C
11a. PSH, group 14C
11b. PSP, group 14C
12a. PSH, group 14US
12b. PSP, group 14US

1. Muscle repair is microscopically characterized by a central zone (CZ) filled with inflammatory cells, a well cellularized surrounding regeneration zone (RZ) where myogenic differentiation takes place, and a surviving zone (SZ) that corresponds to the uninjured segments of muscle fibers. 2. Several myotubes (➔), surviving myofibres (★), inflammatory reaction(⇨). Note, collagenous fibers are strongly stained in red and are aligned roughly parallel to myotubes. 3. Muscle cells (mc) at the SZ, thin collagenous fibers at the RZ and at the endomysium (➔). 4. Muscle cells (mc) at the SZ, thick collagen fibers at the RZ (►) and also at the endomysium (➔). 5. Inflammatory tissue at the CZ, myotubes weakly labeled at the RZ, one can notice that some are fused to the surviving stumps (➔). 6. Well cellularized connective tissue (★) and the arrow shows a myotube with multiple centrally located nuclei (inset). 7. Some newly formed, thin, weakly birefringent collagenous fibers all around the RZ. 8. Many thick brilliant collagenous fibers at the RZ, near the SZ, which becomes thinner towards the CZ, these thick collagenous septa maintained their roughly parallel orientation to myotubes. 9. Well cellularized connective tissue at the CZ with newly formed myotube that has succeeded in extending across the entire lesion gap (➔). 10. Thin collagenous fibers (intense red) surrounding several myotubes. 11a. Collagenous fibers strongly stained in red and muscle cells with clear cytoplasm, forming a multidirectional arrangement at the CZ, in sharp contrast with peripheral muscle cells. 11b. Thin collagenous fibers following the RZ cells orientation. 12a. Note that collagenous fibers are plentiful, but one can notice the more regular pattern of the tissue comparing to the other picture. 12b. Thicker collagenous fibers at the RZ (►), that becomes thinner at the CZ, following the regenerating muscle cells orientation.

QUALITATIVE ASPECTS OF THE DESMIN IMMUNOHISTOCHEMICAL REACTION

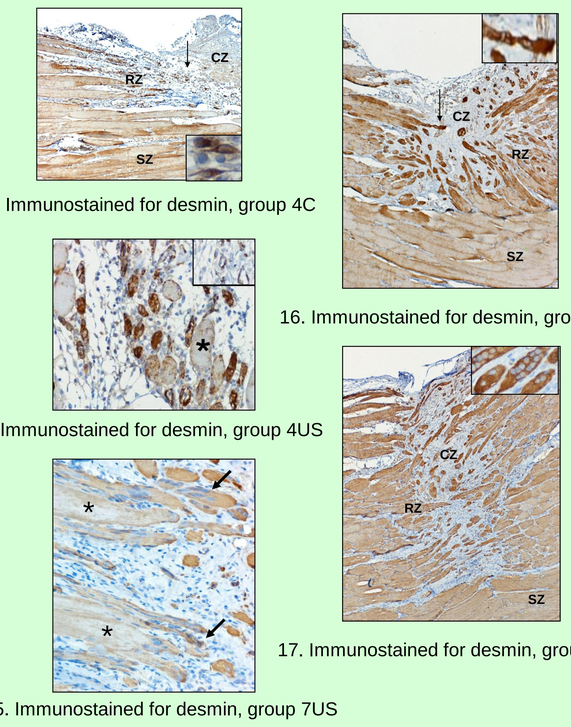

13. Immunostained for desmin, group 4C
14. Immunostained for desmin, group 4US
15. Immunostained for desmin, group 7US
16. Immunostained for desmin, group 14C
17. Immunostained for desmin, group 14US

13. Muscle cells labeled in brown at the SZ, weak labeled at the RZ and at the CZ, where the arrow indicates desmin-positive mononucleated cells which display a characteristic spindle shape correspond to myoblasts (inset). 14. Several newly formed myotubes strongly labeled, surviving muscle cells(★); note that the vessels wall are also positive labeled for desmin (inset). 15. Myotubes in different development stages (➔) and muscle cells in regeneration process (★). 16. Myotubes been cutted in several directions suggesting tissue desorganization; the arrow indicates the fusion of one myotube to a surviving muscle cell (inset). 17. One can notice the more regular pattern of the myotubes and myofibers muscle cells which are aligned roughly parallel to each other almost enclosing the CZ. The inset shows young myotubes indicating celular differentiation at 14 days post-lesion.

MORPHOMETRY OF FIBRILAR COLLAGEN AND REGENERATING MUSCLE CELLS

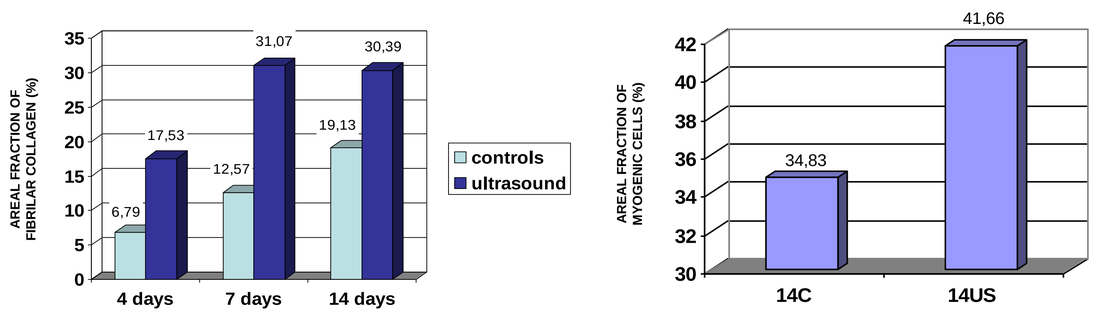

CONCLUSIONS

Our data suggest that although the pulsed US induced the deposition of collagenous fibers, there was a larger amount of myotubes at 14 days post-trauma in US treated lesions, suggesting that the increase on collagen deposition and aggregation promoted by the US was not enough to impair muscle cells growth and differentiation.

REFERENCES

T.A. Jarvinen, T.L.N. Jarvinen, M. Kaariainen, H. Kalimo, M. Jarvinen, **Muscle injuries – biology and treatment**, Am. J. Sports Med. 33 (2005) 745–764.

L.C.U. Junqueira, W. Cossermelli, R.R. Brentani, **Differential staining of collagenous type I, II and III by Sirius red and polarization microscopy**, Arch. Histol. Jpn. 41 (1978) 267–274.

M. Dyson, J.B. Pond, J. Joseph, R. Warwick, **The stimulation of tissue regeneration by means of ultrasound**, Clin. Sci. 35 (1968) 273– 285.

J. Rantanen, O. Thorsson, P. Wollmer, T. Hurme, H. Kalimo, **Effects of therapeutic ultrasound on the regeneration of skeletal myofibers after experimental muscle injury**, Am. J. Sports Med. 27 (1999) 54–59.

J.L. Karnes, H.W. Burton, **Continuous therapeutic ultrasound accelerates repair of contraction-induced skeletal muscle damage in rats**, Arch. Phys. Med. Rehabil. 83 (2002) 1–4.

L.D. Wilkin, M.A. Merrick, T.E. Kirby, S.T. Devor, **Influence of therapeutic ultrasound on skeletal muscle regeneration following blunt contusion**, Int. J. Sports Med. 25 (2004) 73–77.

ABSTRACT

Effect of Ultrasound Therapy on the Repair of Gastrocnemius Muscle Injury in Rats

BACKGROUND: Considering that ultrasound (US) treatment stimulates both proliferation of myogenic cells and collagen deposition which, theorically, could impair further cell proliferation, it was thought to be of interest to proceed to a quantitative study of collagen and myogenic cells in a rat muscle lacerated injury model treated by pulsed US.

METHODS: Morphometric techniques in association with the Picrosirius-polarization method (for collagen identification) and with immunodetection of desmin (a myogenic cells marker) were carried out in tissue sections. We compared untreated operated controls with animals treated daily with 1MHz pulsed US(50%) at 0.57 W/cm² for 5min (beginning 2 days post-trauma). Five treated and five control animals were sacrificed at 4, 7 or 14 days post-trauma.

RESULTS: The areal fraction (in percentage) occupied by collagen was higher in treated lesions in all post-injury time spans studied: 4 days (17.53±6.2 *vs* 6.79±1.3, p=0.0491), 7 days (31.07±7.4 *vs* 12.57±3.6, p=0.0021) and 14 days (41.66±2.97 *vs* 34.83±3.08, p=0.025). The areal fraction of myoblasts and myotubes was larger in the treated lesions at 14 days after surgery (41.66±2.97 *vs* 34.83±3.08, p=0.025). Figure 1-8 illustrate our results.

CONCLUSIONS: Our data suggest that although the pulsed US induced the deposition of collagenous fibers, there was a larger amount of myotubes at 14 days post-trauma in US treated lesions, suggesting that the increase on collagen deposition and aggregation promoted by the US was not enough to impair muscle cells growth and differentiation.

DISCLOSURES: Supported by LIM FMUSP and published in ***Ultrasonics*** *48,* 403-11, 2008.